

Dr. Brian L. Wilk, DMD
 Highpoint Dental Medicine
 200 Highpoint Drive, Suite 220
 Chalfont, PA, USA
 highpointdental.com
 drwilk@highpointdental.com



Tony Cirigliano, CDT
 Broadway Dental Laboratory
 301 East Pennsylvania Blvd.
 Feasterville, PA, USA
 broadway-dental.net

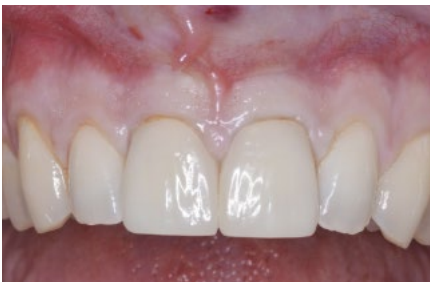
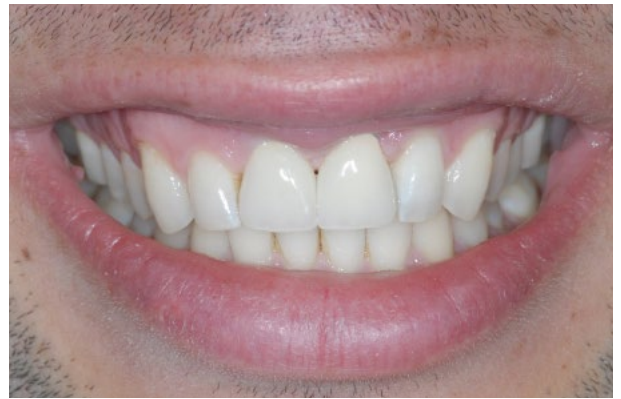
Barry P. Levin, DMD
 Diplomate, American Board of Periodontology
 Clinical Associate Professor, University of Pennsylvania
 Center for Periodontics and Dental Implant Surgery
 509 York Rd. Jenkintown, PA, 19046, USA
 www.aperiodoc.com

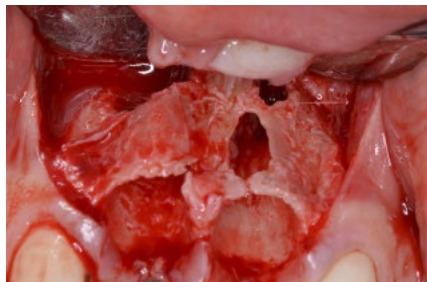


Restoration of central incisors using a staged approach for an optimal esthetic result

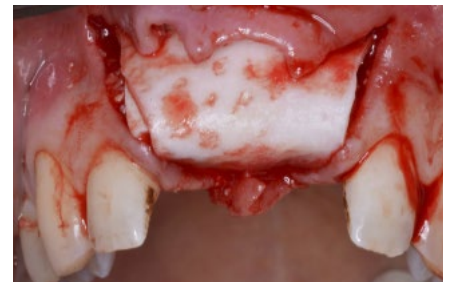
A 24-year old male presented with failing endodontic therapy of both central incisors. A multi-staged approach was used to treat the infection and graft the bone and soft tissue for an optimal esthetic outcome. After proper tissue and bone augmentation, two straight OsseoSpeed EV 4.2 implants were placed and subsequently temporized, and then restored with ATLANTIS patient-specific abutments utilizing ATLANTIS IO FLO scan bodies and a TRIOS (3Shape) intraoral digital scanner. Implant treatment of the two central incisors was selected after numerous failed endodontic treatments and the treatment was considered more efficient and a predictable method of therapy. Using technology such as intraoral scanning for ATLANTIS abutments, the streamlined digital workflow was utilized to enhance an optimal patient-specific outcome throughout the process.



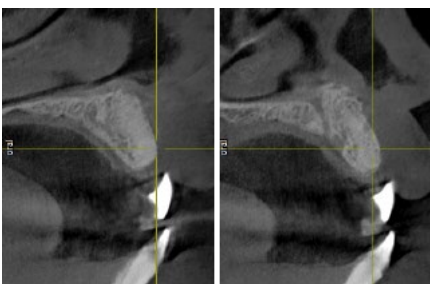
1. Pre-treatment situation with teeth #11 and #21 demonstrating minimal marginal inflammation. Significant apical and facial bone defects exist.



2. Following extractions, the large osseous defects are debrided prior to grafting.

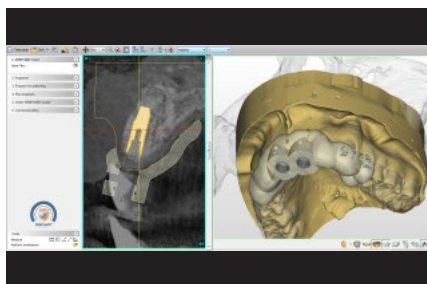


3. After grafting the two sockets/defects, a cross-linked collagen barrier is covered with SYMBIOS PerioDerm for additional soft-tissue augmentation as an alternative to an autogenous, subepithelial, connective tissue graft.

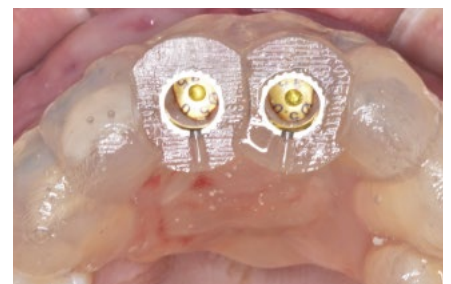

Tooth #11 position Tooth #21 position

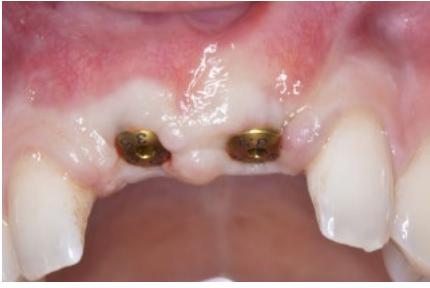4. Six-month CBCT cross-sectional image demonstrating complete reconstruction of alveolar ridge in #11 and #21 positions.



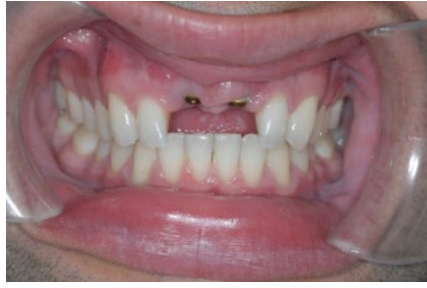5. Tooth #21 position. 3D implant planning demonstrating dentition scan matched on the CBCT scan and allowing digital review of the SIMPLANT Guide design.



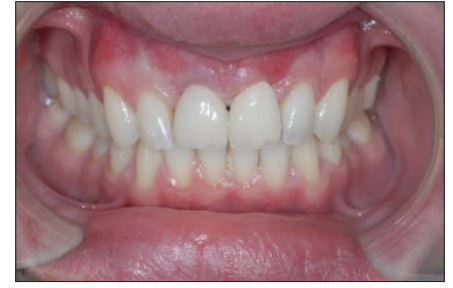6. SIMPLANT Guide showing minimally-invasive, guided implant surgery.



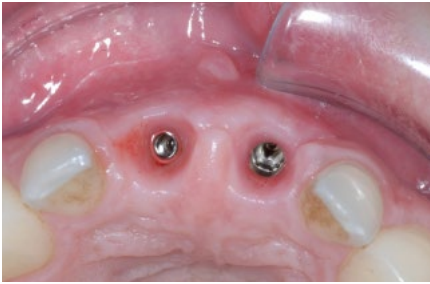7. Implant placement in the #11 and #21 positions OsseoSpeed EV 4.2 S x 13.0 mm implants.



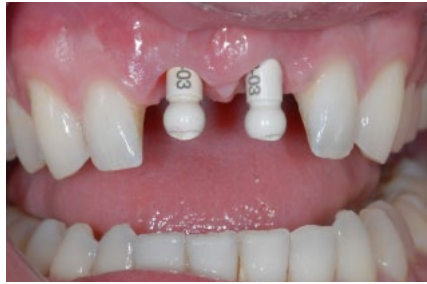8. Two months after implant placement, the soft and hard tissues are allowed to heal with a relieved interim maxillary RPD (Flipper).



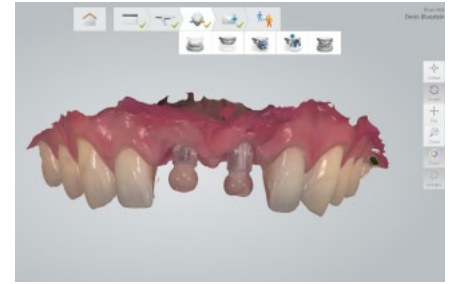
9. Laboratory processed provisional restoration in place to promote papillae growth in all interproximal embrasures.



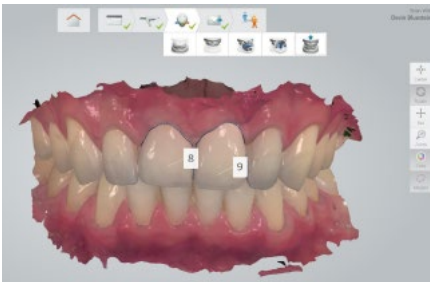10. Removal of temporary restorations showing sculpted soft tissue contours and gingival health. As a result of provisionalization, the interdental papillae were recreated along with excellent emergence profile.



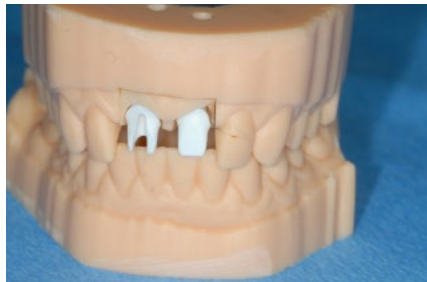11. Intraoral scanning was performed with an ATLANTIS IO FLO seated in the OsseoSpeed EV implants. A TRIOS (3Shape) intraoral scanner was used to scan the soft tissue and opposing arch.



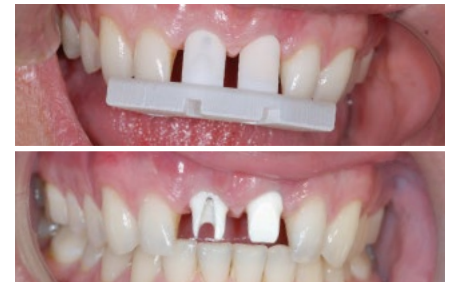
12. Facial view of intraoral scanning for ATLANTIS abutments with TRIOS (3Shape).



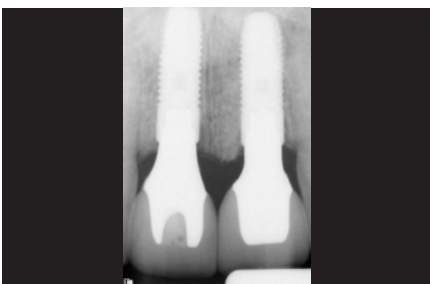
13. Scan of the final temporary restorations to aid in design and location of the margins of full contour ATLANTIS abutments in zirconia.



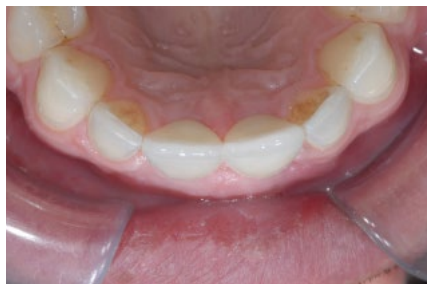14. Printed model with ELOS Accurate Model Analogs and ATLANTIS abutments.



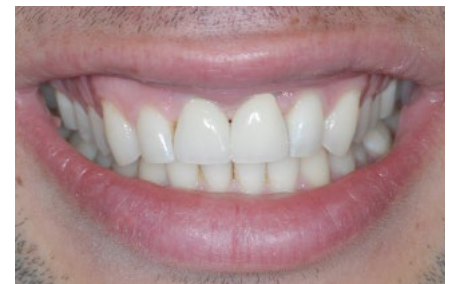15. Placement of ATLANTIS patient-specific abutments in zirconia using ATLANTIS Insertion Guide. Designed specifically to seat in one position-only on OsseoSpeed EV implants, are placed and torqued to 25 Ncm.



16. Radiograph of ATLANTIS abutments in zirconia and e.max crowns cemented to the abutments shows ideally contoured abutments to promote long-term stability of both hard and soft tissues.



17. Occlusal view of ideally contoured restorations.



18. After one year, healthy tissue response and natural looking esthetics achieved with final restorations.